

Mechanism of Action (MOA)

INTRODUCTION AND OVERVIEW

The Ulthera® System was cleared by the FDA in late 2009 for a non-invasive eyebrow lift indication following a full face treatment and is currently marketed worldwide in over 50 countries. In late 2012, the FDA cleared the Ulthera System to be safe and effective for the lifting of lax submental (beneath the chin) and neck tissue. This white paper describes how Ultherapy lifts the skin based on the known physiologic processes of collagen denaturation, wound healing, and neocollagenesis. This document will also discuss the effects of certain medications such as non-steroidal anti-inflammatory medications (NSAIDs) on inflammation and how this could potentially impact the wound healing process essential to Ultherapy's Mechanism of Action (MOA).

The Ulthera System uses microfocused ultrasound with visualization (MFU-V) to lift and tighten the skin through specific mechanisms. The initial lift seen immediately after an Ultherapy treatment arises from thermally induced collagen coagulation, denaturation and contraction within precise, well-defined lesions. The creation of these lesions leads to an inflammatory wound-healing response which stimulates long-term tissue remodeling and leads to further lifting and tightening. Both stages of lift that occur following Ultherapy are described in further detail below.

First Stage: Collagen Denaturation

Ultherapy focuses ultrasound waves to precise, well-defined areas in dermal and subcutaneous tissue which causes the creation of distinct Thermal Coagulation Points (TCPs)¹⁻³. Current treatment guidelines call for the creation of ~16,000 of these TCPs at various depths in the tissue during a full face and neck treatment (Figure 1).

In a publication by White and colleagues, they state that ultrasound waves induce a vibration in molecules within the targeted tissues, and the resulting molecular friction generates heat¹. This heat, generated by Ultherapy's ultrasound waves, generally reaches temperatures of ~60-70°C at the focus of the TCP¹⁻³. This is important because collagen, a protein within skin dermal and subdermal layers (including the superficial musculoaponeurotic system (SMAS)), begins to lose its organized structure and eventually denatures at these temperatures. Studies indicate that collagen fibrils, when heated to a specific temperature over a period of time, will contract because the intramolecular hydrogen bonds in the collagen structure are broken (Figure 2). Using microthermal analysis, Bozec and Odlyhan (2011)

demonstrated that the internal cross-links holding the collagen fibrils together begins to break at a threshold temperature of ~58°C, with the main transition to denaturation occurring at ~65°C (Figure 3)⁴. **This phenomenon explains the contraction of collagen that leads to the observed initial lift in the tissue immediately following an Ultherapy treatment.**

Additionally, other studies have demonstrated that shrinkage in collagen fibrils is evident at ~57°C, with further disruption and more complete denaturation of the collagen fibril at 60°C⁵. Hayashi et al, demonstrated that the tissue shrinkage or lift that results as a result of the collagen denaturation ranges from 11% at 65°C to a maximum of 59% at 80°C and generally occurs within less than 2 minutes of heat application. Reaching these threshold temperatures during an Ultherapy treatment are important in order to optimize the effect on collagen denaturation, which ultimately leads to collagen synthesis. As stated above, this initial shrinkage in collagen fibrils results in the initial lift observed after Ultherapy. It should also be noted that some of the

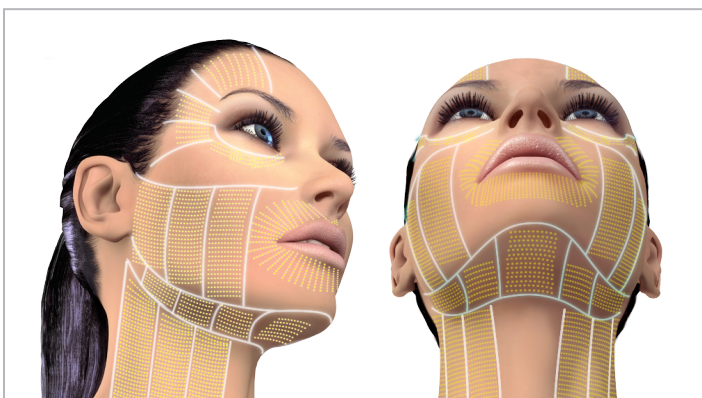


Figure 1
Approximately 16,000 discrete coagulation points are placed at multiple depths, causing immediate tissue contraction and initiating neocollagenesis.

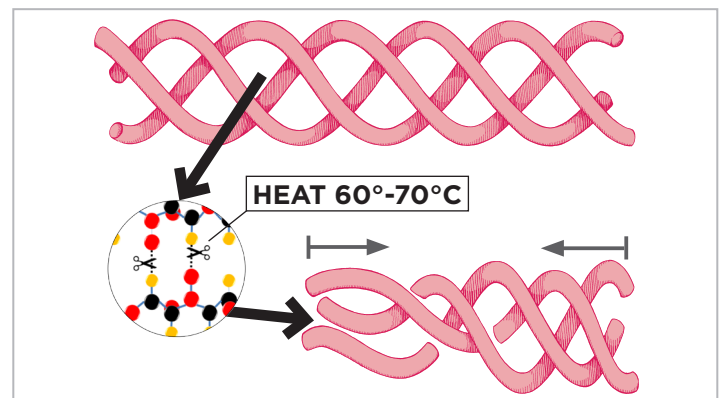


Figure 2
The application of heat at specific temperatures to tissue disrupts and breaks the hydrogen bonds holding the collagen fibrils together, resulting in contraction of the collagen structure.

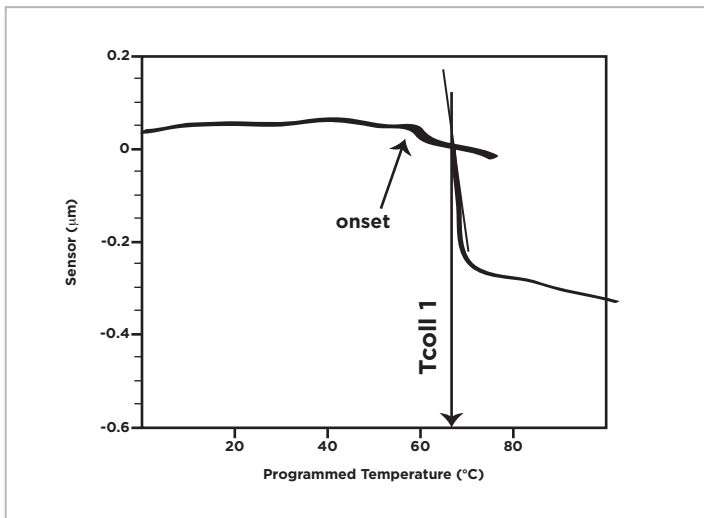


Figure 3

To understand the effect of an increase of temperature on collagen, localized thermo-mechanical analysis (L-TMA) was performed on a collagen fibril. The onset temperature at ~58° C is explained by conformational changes occurring within the fibrils such as partial shrinkage of the fibrils. The main transition event at ~65°C corresponds to the process of breaking of the internal cross-links and collagen denaturation ⁴.

immediate cosmetic improvements that the patient and clinician observe after Ultherapy treatment can be attributed to mild edema. Edema, or swelling due to the accumulation of fluid in the tissue, is the body’s response to acute “injury”, i.e. creation of TCPs in the skin. This mild swelling can serve to temporarily “plump” the skin, contributing to possible aesthetically-pleasing, albeit transient, effects.

Following the initial thermal-induced collagen contraction and denaturation, the next phase of Ultherapy’s MOA occurs: that being neocollagenesis and collagen remodeling.

Second Stage: Neocollagenesis and Collagen Remodeling

The TCPs created by Ulthera’s MFU-V technology are recognized by the body as an “injury”, thereby initiating the wound healing response. This response involves tissue repair and synthesis of new collagen which undergoes organization and cross-linking, enabling it to have more viscoelastic properties and better resist mechanical stresses ⁶. Over time, this leads to tissue lifting and tightening. There are three overlapping stages associated with this stage of lifting (Figure 4).

Inflammation

During this phase, cells called macrophages play an important role in breaking down and phagocytizing (engulfing) “injured” tissue and releasing cytokines (signaling molecules) that attract fibroblasts (a type of cell that synthesizes collagen). Other factors released during this phase also contribute to the breakdown of denatured collagen and the synthesis of new collagen ⁷. A study in which tissue was heated to the collagen denaturation range (~60-70°C) demonstrated a significant inflammatory response at the site of “injury” from day 2 for up to 10 weeks post treatment ⁸. The infiltration of macrophages into the “injured” site is crucial to the inflammatory response and the healthy intervening tissue between TCPs plays an important role in this ^{1,9}. The extent of thermal induced dermal injury is a limiting factor for the wound healing response and areas with necrosis would not heal as efficiently as TCPs surrounded by “islands” of tissue that promote infiltration of inflammatory cells and efficient healing ^{8,10-12}. Upon exposure to certain molecules, such as heat-shock protein (HSP), macrophages become activated and influence wound healing by stimulating the proliferation of cells such as fibroblasts that promote the repair and remodeling of the TCPs ^{13,14}.

Proliferation

This phase can overlap with inflammation and is generally characterized by fibroblasts synthesizing new collagen (mainly Type III) and other mediators important to rebuilding the collagen matrix such as elastin, fibronectin, glycosaminoglycans, and proteases. Studies with thermal heat treatment of human skin demonstrate that

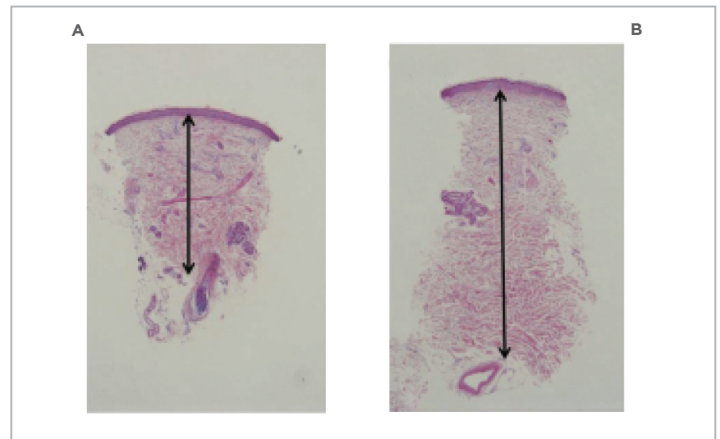


Figure 5

Histology of skin biopsies from lateral cheek showed that dermal thickness was greater after Ultherapy treatment (B) compared to baseline (A) ¹⁵.

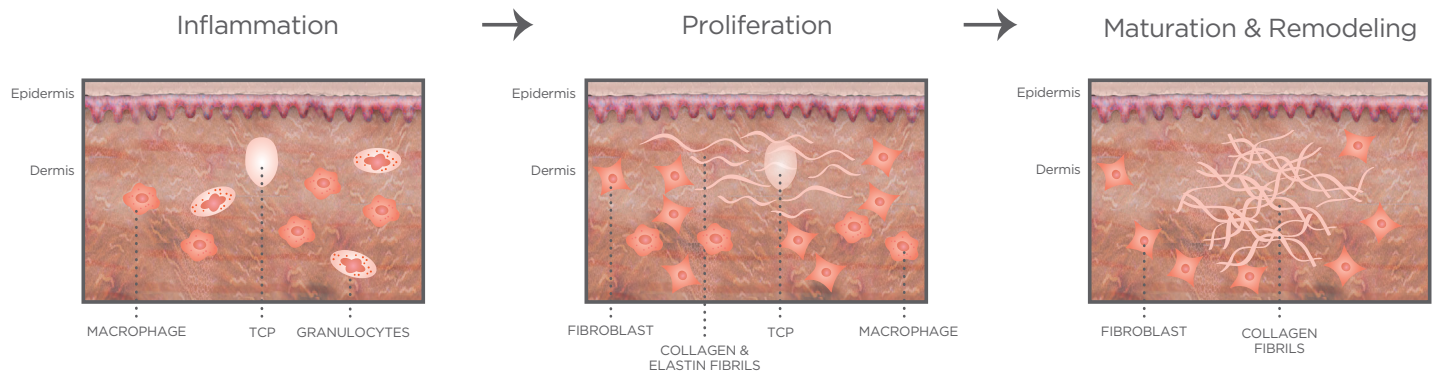


Figure 4

	Mean±Standard Deviation			
	Before Ultherapy	After Ultherapy	Change (%)	P-value
Average area fraction of collagen (%)				
Papillary dermis	54.38 ± 10.89	55.58 ± 8.22	2.2	0.26
Reticular dermis	52.70 ± 7.79	65.18 ± 7.89	23.7	0.001
Dermal thickness (mm)	1.32 ± 0.18	1.63 ± 0.31	65.9	0.001

Table 1

Average fraction of collagen and dermal thickness before and after Ultherapy treatment¹⁵.

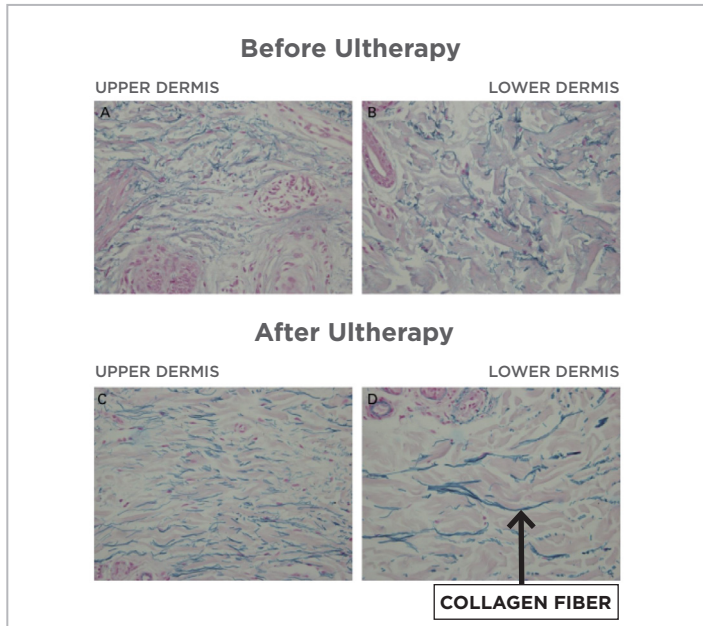


Figure 6

In skin biopsy samples taken from the lateral side of the cheek 2 months after Ultherapy treatment, the elastic fibers of the upper and lower reticular dermis were more parallel and straighter in appearance than samples taken before treatment¹⁵.

fibroblasts are seen within the focal injury zone by day 28, suggesting that active dermal remodeling has begun⁸. A significant increase in the amount of elastin is also evident. Suh et al., (2011)¹⁵ performed histological analysis on facial skin treated with Ultherapy and noted that the average area fraction of collagen in the reticular dermis significantly increased by 23.7% over baseline and overall dermal thickness was greater (Table 1, Figure 5). Furthermore, the elastic fibers of the upper and lower reticular dermis were more parallel and straighter in appearance than samples taken before treatment (Figure 6).

Maturation and Remodeling

This phase generally starts at 3 weeks and can last for up to a year. This phase mainly represents the period during which type III collagen is replaced by type I collagen, which forms tight cross-links with itself and other proteins. Studies have demonstrated the increased production of type I collagen during the wound healing response to thermal injury¹⁶. Meshkinpour and colleagues found increased collagen production in skin biopsies even 12 months after thermal heat treatment¹⁷. The collagen remodeling process is a crucial step in facial skin tightening and lifting by Ultherapy. Studies have clearly demonstrated a zone of new collagen growth (neocollagenesis) in denatured tissue that coincides with the zone of dermal remodeling and old collagen⁸. The remodeling process,

driven by the collagen chaperone HSP47, leads to complete replacement of thermal injury zones with new collagen by 10 weeks post-treatment⁸. Generally, the duration of this phase is dependent upon factors such as patient age and racial differences in skin tissue. In general, increased patient age can be associated with delayed onset of healing, protraction of phases and an inability to reach the same level of healing. Advanced age may also be associated with decreased tensile strength of the ‘wound’ after repair.

Effect of Medications on Inflammation and Wound Healing

A wide variety of pharmacologic and non-pharmacologic approaches are used for pain management during Ultherapy; however, as some medications have the potential to interfere with the wound healing response, clinicians may wish to know how to treat potential pain and swelling associated with treatment without affecting outcome. Anti-inflammatory medications such as NSAIDs (e.g. ibuprofen, celecoxib) non-selectively inhibit both cyclooxygenase (COX-1 and COX-2) enzymes, resulting in the decreased production of prostaglandins. Prostaglandins are important players in the wound healing response because they are involved in the production of hyaluronic acid, a carbohydrate found in connective tissue and needed during the proliferative phase of wound healing^{18,19}. Prostaglandins also act as both inflammatory mediators and fibroblast modulators, which as we discussed, are involved in the synthesis of collagen²⁰. In animal models, systemic chronic use of ibuprofen has demonstrated an anti-proliferative effect on wound healing, resulting in decreased numbers of fibroblasts and reduced wound contraction²¹⁻²³. As stated in our Comfort Management White Paper, we generally recommend one 800 mg dose of ibuprofen one hour before treatment - as this had comparable analgesic effect as that of narcotics in a double-blind controlled study. The half-life of ibuprofen is only 4 hours so it’s highly unlikely this single dose will impact the inflammatory process in an appreciable manner given that inflammatory mediators will be present long after the Ultherapy treatment ends and tissue remodeling continues for up to a year after treatment, as previously mentioned. However, it is important to consider the mechanism of action of anti-inflammatory agents during chronic use and how this may potentially interfere/interact with the desired inflammation that arises after Ultherapy treatment. As noted above, the inflammatory process is crucial to lifting and treatment efficacy with Ultherapy.

Other Factors Affecting Wound Healing

Certain diseases such as diabetes can also affect wound healing in numerous ways. Studies of injured tissue suggest a delayed response to injury and impaired functioning of immune cells, such as

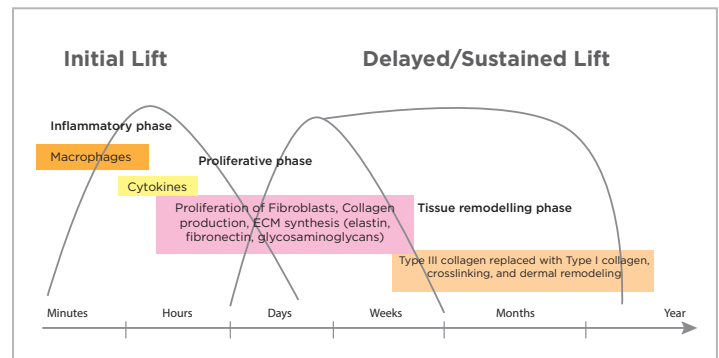


Figure 7

fibroblasts²⁴⁻²⁶. Other systemic factors such as obesity, nutritional status of the individual and stress have also been shown to interfere with one or more phases of this process, thus causing improper or impaired wound healing²⁷.

CONCLUSION

Ultherapy[®] is currently the only technology that precisely and consistently heats tissues to 60-70°C, the optimal temperatures for collagen contraction and denaturation at specific depths. The initial post-treatment lift occurs due to the contraction and denaturation of collagen within the TCPs. The second stage of lifting occurs when the body's wound healing response repairs the "injury" caused by the heat and builds new collagen with enhanced viscoelastic properties (neocollagenesis) over a period of time (Figure 7). This white paper outlines Ultherapy's MOA based on evidence from studies that use ultrasound and other thermal energy to heat human tissue to the collagen denaturation temperature range. Data from these studies explains the molecular background for Ultherapy's unique "lift" indication. Finally, we also discuss the possible effects of NSAIDs and other factors on the wound healing process and how consideration should be taken when certain medications are prescribed for chronic use after an Ultherapy treatment.

REFERENCES

1. White WM, Makin IR, Barthe PG, Slayton MH, Gliklich RE. Selective creation of thermal injury zones in the superficial musculoaponeurotic system using intense ultrasound therapy: a new target for noninvasive facial rejuvenation. *Arch Facial Plast Surg*. 2007;9(1):22-29.
2. White WM, Makin IR, Slayton MH, Barthe PG, Gliklich R. Selective transcutaneous delivery of energy to porcine soft tissues using Intense Ultrasound (IUS). *Lasers in surgery and medicine*. 2008;40(2):67-75.
3. Laubach HJ, Makin IR, Barthe PG, Slayton MH, Manstein D. Intense focused ultrasound: evaluation of a new treatment modality for precise microcoagulation within the skin. *Dermatologic surgery : official publication for American Society for Dermatologic Surgery [et al.]*. 2008;34(5):727-734.
4. Bozec L, Odlyha M. Thermal denaturation studies of collagen by microthermal analysis and atomic force microscopy. *Biophys J*. 2011;101(1):228-236.
5. Lin SJ, Hsiao CY, Sun Y, et al. Monitoring the thermally induced structural transitions of collagen by use of second-harmonic generation microscopy. *Opt Lett*. 2005;30(6):622-624.
6. Christiansen DL, Huang EK, Silver FH. Assembly of type I collagen: fusion of fibril subunits and the influence of fibril diameter on mechanical properties *Matrix Biology*. 2000;19:409-420.
7. Agren MS, Taplin CJ, Woessner JF, Jr., Eaglstein WH, Mertz PM. Collagenase in wound healing: effect of wound age and type. *J Invest Dermatol*. 1992;99(6):709-714.
8. Hantash BM, Ubeid AA, Chang H, Kafi R, Renton B. Bipolar fractional radiofrequency treatment induces ne elastogenesis and neocollagenesis. *Lasers Surg Med*. 2009;41(1):1-9.
9. Gliklich RE, White WM, Slayton MH, Barthe PG, Makin IR. Clinical pilot study of intense ultrasound therapy to deep dermal facial skin and subcutaneous tissues. *Arch Facial Plast Surg*. 2007;9(2):88-95.
10. Hantash BM, Bedi VP, Kapadia B, et al. In vivo histological evaluation of a novel ablative fractional resurfacing device. *Lasers Surg Med*. 2007;39(2):96-107.
11. Zelickson BD, Kist D, Bernstein E, et al. Histological and ultrastructural evaluation of the effects of a radiofrequency-based nonablative dermal remodeling device: a pilot study. *Arch Dermatol*. 2004;140(2):204-209.
12. Dierickx CC. The role of deep heating for noninvasive skin rejuvenation. *Lasers Surg Med*. 2006;38(9):799-807.
13. Mosser DM, Edwards JP. Exploring the full spectrum of macrophage activation. *Nat Rev Immunol*. 2008;8(12):958-969.
14. Rappolee DA, Mark D, Banda MJ, Werb Z. Wound macrophages express TGF- α and other growth factors in vivo: analysis by mRNA phenotyping. *Science*. 1988;241(4866):708-712.
15. Suh DH, Shin MK, Lee SJ, et al. Intense focused ultrasound tightening in asian skin: clinical and pathologic results. *Dermatologic surgery : official publication for American Society for Dermatologic Surgery [et al.]*. 2011;37(11):1595-1602.
16. Zelickson BD, Kist D, Bernstein E, et al. Histological and ultrastructural evaluation of the effects of a radiofrequency-based nonablative dermal remodeling device: a pilot study. *Arch Dermatol*. 2004;140(2):204-209.
17. Meshkinpour A, Ghasri P, Pope K, et al. Treatment of hypertrophic scars and keloids with a radiofrequency device: a study of collagen effects. *Lasers Surg Med*. 2005;37(5):343-349.
18. Murota S, Chang WC, Abe M, Otsuka K. The stimulatory effect of prostaglandins on production of hexosamine-containing substances by cultured fibroblasts. *Prostaglandins*. 1976;12(2):193-195.
19. Murota S, Abe M, Otsuka K. Stimulatory effect of prostaglandins on the production of hexosamine-containing substances by cultured fibroblasts (3) induction of hyaluronic acid synthetase by prostaglandin F $_{2\alpha}$. *Prostaglandins*. 1977;14(5):983-991.
20. Sandulache VC, Parekh A, Li-Korotky H, Dohar JE, Hebda PA. Prostaglandin E2 inhibition of keloid fibroblast migration, contraction, and transforming growth factor (TGF)- β 1-induced collagen synthesis. *Wound Repair Regen*. 2007;15(1):122-133.
21. Dong YL, Fleming RY, Yan TZ, Herndon DN, Waymack JP. Effect of ibuprofen on the inflammatory response to surgical wounds. *J Trauma*. 1993;35(3):340-343.
22. Dvivedi S, Tiwari SM, Sharma A. Effect of ibuprofen and diclofenac sodium on experimental wound healing. *Indian J Exp Biol*. 1997;35(11):1243-1245.
23. Krischak GD, Augat P, Claes L, Kinzl L, Beck A. The effects of non-steroidal anti-inflammatory drug application on incisional wound healing in rats. *J Wound Care*. 2007;16(2):76-78.
24. Rosenberg CS. Wound healing in the patient with diabetes mellitus. *Nurs Clin North Am*. 1990;25(1):247-261.
25. Greenhalgh DG. Wound healing and diabetes mellitus. *Clin Plast Surg*. 2003;30(1):37-45.
26. Verhofstad MH, Bisseling TM, Haans EM, Hendriks T. Collagen synthesis in rat skin and ileum fibroblasts is affected differently by diabetes-related factors. *Int J Exp Pathol*. 1998;79(5):321-328.
27. Guo S, Dipietro LA. Factors affecting wound healing. *J Dent Res*. 2010;89(3):219-229.